

SURGICAL TREATMENTS OF OBSTRUCTIVE SLEEP APNEA IN SEOUL NATIONAL UNIVERSITY OF DENTAL HOSPITAL

Jin-Young CHOI

Department of Oral & Maxillofacial Surgery, School of Dentistry, Seoul National University

Citation: Jin-Young CHOI, Surgical treatments of obstructive sleep apnea in Seoul National University of Dental Hospital. Journal of Biomedicine and Practice, 2018, vol. 1, issue. 2, pp.13–19.

Received 23 April 2018

Accepted 21 May 2018

Corresponding author: Jin-Young CHOI, Department of Oral & Maxillofacial Surgery, School of Dentistry, Seoul National University, 275-1, Yeongun-Dong Chongro-Ku Seoul, 110-768 South Korea, tel: +82-2072-3992, E-mail: jinychoi@snu.ac.kr

<http://dx.doi.org/10.26739/2181-9300-2018-2-2>

ANNOTATION

Obstructive sleep apnea (OSA) is a common disorder caused by upper airway collapsibility during sleep. This article describes surgical procedures of OSA performed in the Seoul national university of dental hospital (SNUDH). A treatment OSA varies according to the severity of clinical symptom. In SNUDH, we performed surgical procedures used uvulopalatopharyngoplasty and tonsillectomy, genioglossus muscle advancement, maxillomandibular advancement, tongue base reduction, distraction osteogenesis. If surgeons identify and apply indications of OSA patients, surgical approach is the appropriate alternative for the failure of conservative treatments.

Key words: obstructive sleep apnea, surgical treatments.

Хирургические методы лечения обструктивного апноэ сна в стоматологической клинике Сеульского национального университета

Jin-Young CHOI

Департамент оральной и челюстно-лицевой хирургии, Школа стоматологии, Сеульский национальный университет

Контактная информация: Jin-Young CHOI, Департамент оральной и челюстно-лицевой хирургии, Школа стоматологии, Сеульский национальный университет, 275-1, Yeongun-Dong Chongro-Ku Seoul, 110-768 South Korea, тел: +82-2072-3992, E-mail: jinychoi@snu.ac.kr

АННОТАЦИЯ

Обструктивное апноэ сна является распространенным заболеванием, вызванное полным (апноэ) и частичным (гипопноэ) спаданием верхних дыхательных путей во время сна. В этой статье описаны методы хирургического лечения обструктивного апноэ сна (ОАС) проводимые в Стоматологической клинике Сеульского национального университета (СКЧНУ). Лечение ОАС варьируется в зависимости от тяжести клинических симптомов. В СКЧНУ мы проводили хирургические процедуры, применяли увулопалатофарингопластику и тонзилэктомию, подтяжку подбородочно-язычной мышцы, выдвижение верхней и нижней челюсти, уменьшение задней части языка, дистракционный остеогенез. Если хирурги идентифицируют и учитывают индикации пациентов с ОАС, хирургический подход является подходящей альтернативой для отказа от консервативных методов лечения.

Ключевые слова: обструктивное апноэ сна, хирургическое лечение.

Сеул миллий университетининг стоматологик клиникасида уйқудаги обструктив апноэни жаррохлик даволаш услублари

Jin-Young CHOI

Стоматология ва юз-жағ жаррохлик департаменти, Стоматология мактаби, Сеул миллий университети.

Мурожаат: Jin-Young CHOI, Стоматология ва юз-жағ жаррохлик департаменти, Стоматология мактаби, Сеул миллий университети, 275-1, Yeongun-Dong Chongro-Ku Seoul,



110-768 South Korea, тел: +82-2072-3992, E-mail: jinychoi@snu.ac.kr

АННОТАЦИЯ

Обструктив уйқу апноэси - юқори нафас йулларининг уйқу пайтида коллапси натижасида пайдо бўладиган кенг тарқалган касаллик. Ушбу мақолада Сеул миллий университети стоматологик шифохонасида обструктив уйқу апноэсида утказиладиган жаррохлик даволаш усуллари тасвирланган. Сеул миллий университети стоматологик шифохонасида қуйидаги жаррохлик усуллари қўлланилди, увулопалатофаринго-пластика ва тонзилэктомия, чин-тилли мушакнинг кўтариш, юқори ва пастки жағни кенгайтириш, тилни орқа қисмини камайтириш, дистракцион остеогенез. Агар жаррохлар обструктив уйқу апноэсини аниқласа ва беморларнинг индикацияларини ҳисобга олсалар, жаррохлик ёндашув консерватив терапияни тўхтатиш учун муқобилдир.

Калит сўзлар: уйқудаги обструктив апноэ, жаррохлик даволаш.

Introduction

Obstructive sleep apnea (OSA) is a common disorder caused by upper airway collapsibility during sleep [1]. The common symptoms are snoring and excessive daytime sleepiness. OSA is often associated with compromised upper airway space and increased airway collapsibility [2]. The resulting of hypoxemia provokes fatigue and, excessive daytime sleepiness. Other common features include loud snoring, awakening from gasping or choking, and decrease of cognitive functions [3]. There are additional severely negative consequences including diabetes, heart disease, hypertension, stroke, and a higher risk of motor vehicle accidents from daytime somnolence [4]. In this study, we would like to introduce the surgical procedures applied to the treatment of OSA patients who visit in January 2013 through February 2018 at Seoul National University of Dental Hospital (SNUDH).

Surgical procedures for obstructive sleep apnea

The OSA is a chronic illness at the severe end of the spectrum of sleep-disordered breathing. Continuous positive airway pressure (CPAP) is the accepted first-line treatment for OSA. However,

Table 1

Indication of each surgical treatments for OSA patients

Surgical treatment	Indication
UPPP + Tonsillectomy	- The degree of snoring is severe
	- The obstruction site is localized in the soft palate
	- Large tonsil.
UPPP + Genioglossus Advancement	- The obstruction site is widely spread to not only soft palate but tongue base.
	- Micrognathia
	- Mild to moderate OSA
Maxillomandibular advancement	- OSA patients who has mandibular retrognathism.
	- Multilevel obstruction
	- Severe OSA
Distraction osteogenesis	- OSA pediatric patients who has micrognathia
	- Growing child or adolescent

30% to 50% of patients are not compliant [3]. Patients who fail treatment with CPAP and other conservative measures should be considered for surgical approach. The following surgical procedures used to management of OSA patients at SNUDH. Treatments varied according to the severity of clinical symptom (Table 1).

Uvulopalatopharyngoplasty (UPPP) and tonsillectomy

UPPP accompanying with tonsillectomy has the effect of widening posterior airway by removing excessive soft palate by surgical method [5]. Incision was lied on anterior border of the soft palate, continued to dissect laterally to the tonsil. After the tonsillectomy, posterior part of soft palte including musculature was resected and posterior and anterior pillar were sutured with 4-0 vicryl.

In SNUDH, we performed UPPP surgery to 14 patients, tonsillectomy to 13 patients, and accompanying surgery to 12 patients. (Fig.1)

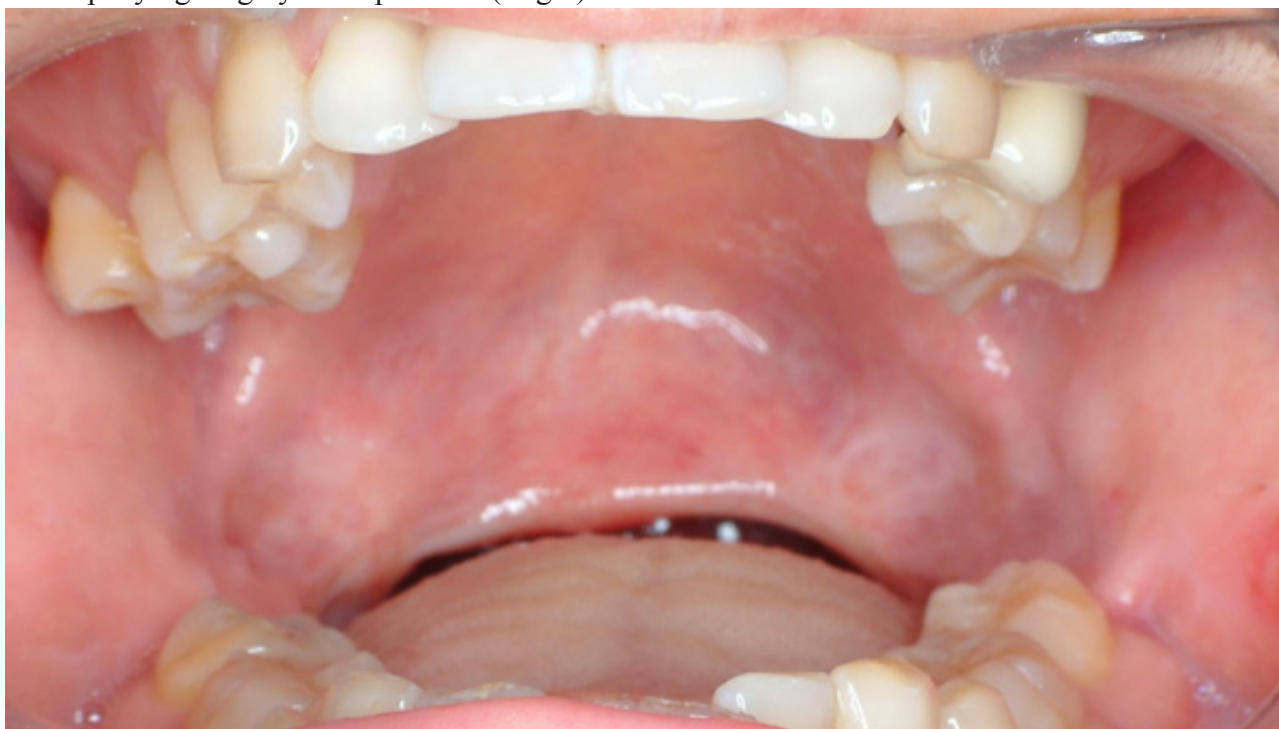

Fig.1: intraoral photo after UPPP

Genioglossus muscle advancement (GA)

GA was reported in 1993 as an option for the surgical treatment of OSA, in the context of phase I of the Stanford University (Powell–Riley) protocol [6]. The rationale for this technique is the placement of tension on the base of the tongue, thus preventing the tongue from falling back into the posterior airway space [7].

An intraoral incision is made in the lower gingivobuccal sulcus between the second premolars bilaterally. The mucosal and submucosal layers are then elevated. The bony incision is made in the mandible with rectangular shape which include Genioglossus muscle. Advancement the cut section of anterior mandible. Then, the genioglossus muscles attached to the genial tubercle are pulled. The authors modified GA into sliding Genioplasty which chin segment include genioglossus muscle.

In SNUDH, we performed GMA surgery to 18 patients, and accompanying with Maxillomandibular advancement to 3 patients. (Fig.2)

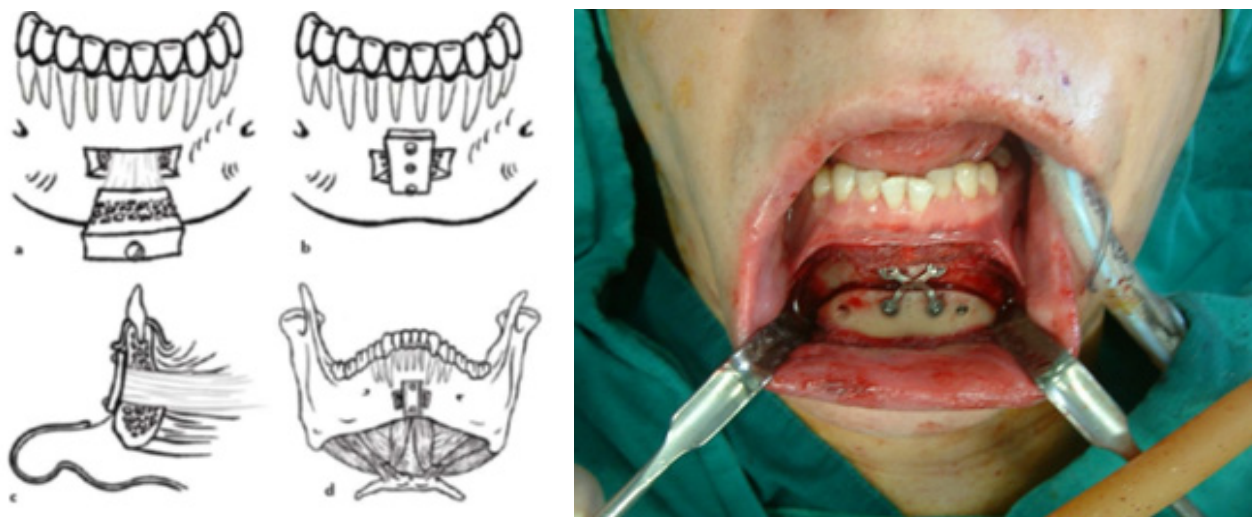


Fig.2: original Genioglossus advancement and modified GA using sliding genioplasty

MaxilloMandibular Advancement (MMA)

MMA has been reported to be the most successful surgical treatment. This procedure results in widening of pharynx and enhances the tension of soft tissue, reducing the collapsibility and obstruction of the pharynx [8]. Conventional orthognathic surgery procedure which is Le fort I osteotomy, bilateral sagittal split osteotomy (BSSO), genioplasty was performed.

In SNUDH, we performed MMA to 14 patients, and accompanying with UPPP surgery to 1 patients. (Fig.3,4)

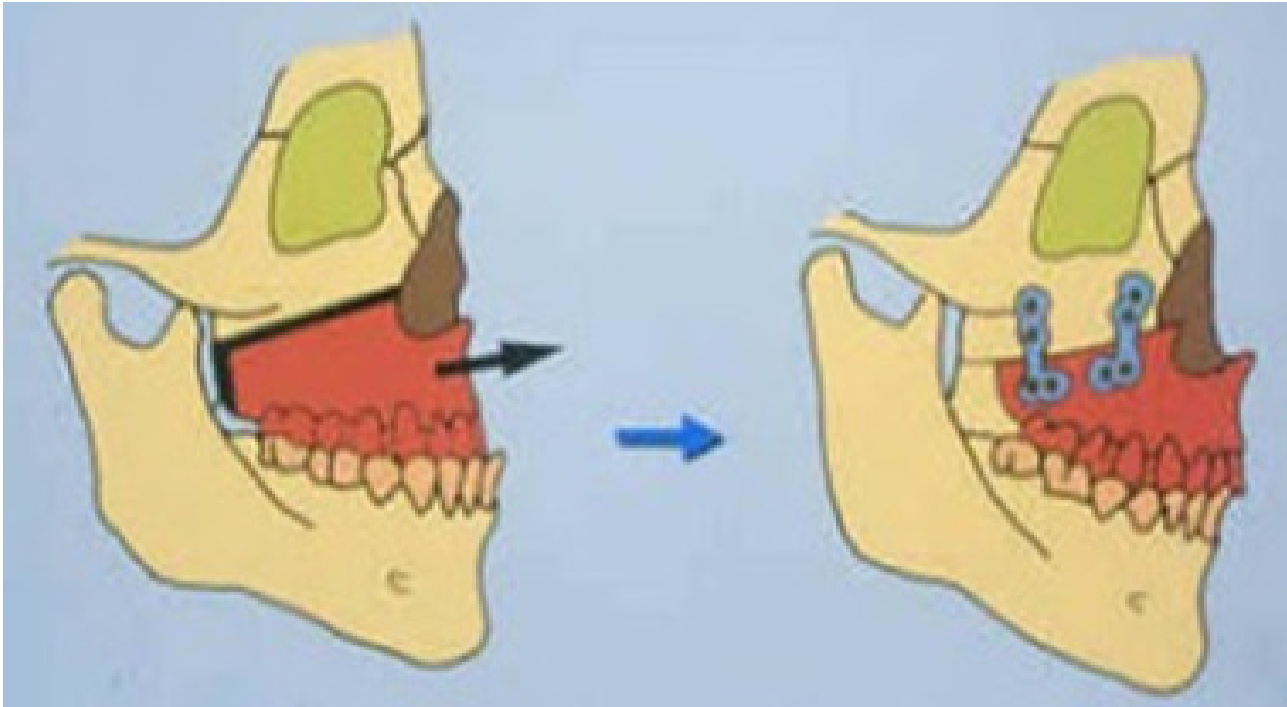


Fig.3: Le Fort I osteotomy for maxilla

Tongue Base reduction

The tongue base can contribute to OSA by collapse into the airway from size alone (macroglossia) or because of hypotonia, retrognathia, or prominent lingual tonsils, or because of combination of all these factors [9].

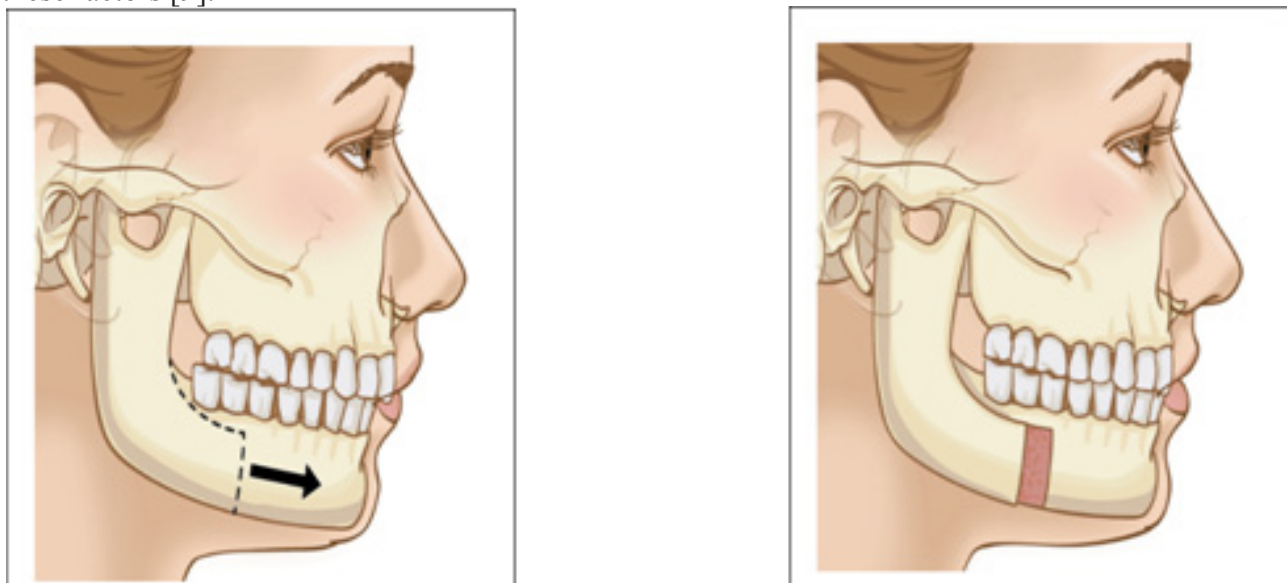


Fig.4 BSSRO(Bilateral Sagittal Split Ramus Osteotomy) for mandible

A midline dorsal tongue incision is made, and flaps are elevated in a submucosal plane to expose the underlying tongue muscle. The tongue muscles are split down to a depth where the transverse muscles meet the genioglossus. After identify the lingual artery and neurovascular bundle, the rest of the lateral tongue musculature is resected little by little.

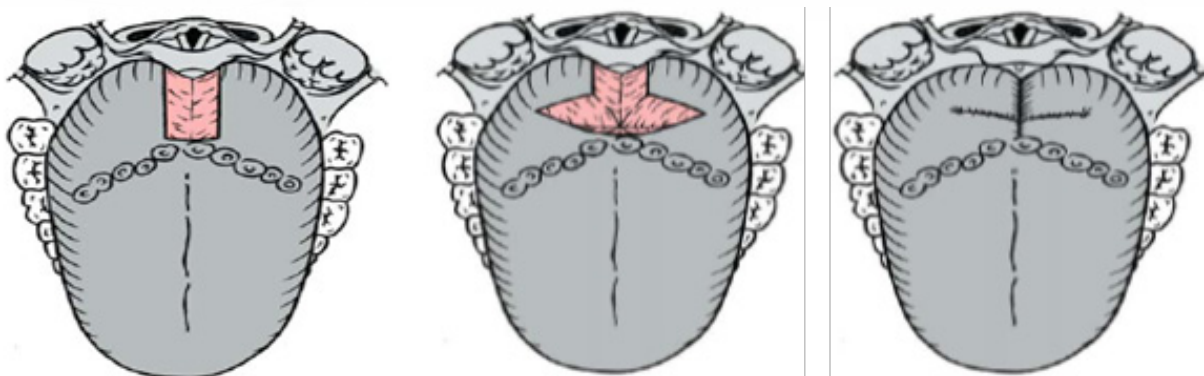


Fig.5: tongue Base reduction

In SNUDH, we performed glossectomy to 2 patients. (Fig.5)

Distraction osteogenesis (DO)

The indications for DO in patients with OSA include infants and children with airway obstruction as a result of congenital micrognathia or midface hypoplasia. These patients may have Treacher Collins or Nager syndromes, craniofacial microsomia, syndromic or nonsyndromic Robin sequence, and syndromic or nonsyndromic midface hypoplasia. They have OSA as a result of severe micrognathia, short posterior face height, malposition of the tongue base [10]. A significant number of these patients are tracheostomy-dependent and they require large advancements (>15 mm) to adequately improve the upper airway [11].

An osteotomy is created and a distraction device is rigidly fixed to the bone. After a latency period of 0 to 7 days to allow regulation of bony metabolism, the device is activated at a rate of 1 mm/ day. After the activation period, consolidation period could be needed for the retention of new born. Bone healing is evaluated by clinical and radiologic examination.

In SNUDH, we performed DO to 2 patients. One of the cases was rigid external distraction osteogenesis device was used and performed tracheostomy. (Fig.6)

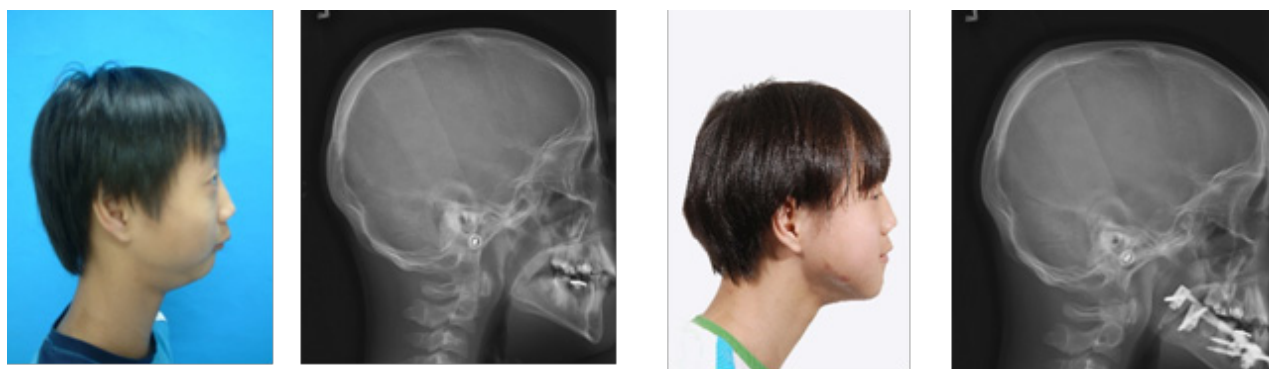


Fig.6: Distraction Osteogenesis

Discussion

Several procedures can be achieved the goals of OSA patients. If surgeon identify and apply indications of OSA patients, surgical approach is the appropriate alternative for the failure of conservative treatments.

Multiple variations of UPPP have been described. However, UPPP does not reliably result in apnea hypopnea index (AHI) normalization and is thus not recommended by the American Academy of Sleep Medicine (AASM) as a single procedure for treating moderate to severe OSA[12]. UPPP can be effective when it accompany with other procedures like tonsillectomy or genioplasty. Patients with a history of palatal surgery should be counseled about the risk of velopharyngeal dysfunction. Consideration also could be given to preoperative speech/swallow assessment for those at high risk of postoperative dysfunction, such as individuals who have undergone previous palatal surgery [13].

GA involves advancement of the genial tubercles and may be accompanied by hyoid suspension. There have been numerous case series with similarly positive results. Riley et al described a 60% success rate out of 223 patients who received both an UPPP and GMA with hyoid suspension for type II upper airway obstruction. "Success" in this study was defined as subjective and objective reports indicating significant improvement equivalent to that seen in patients monitored with nasal CPAP, or if the postoperative respiratory disturbance index was less than 20 with at least a 50% reduction over

the preoperative study [14]. Intraoperative complications of the various GMA procedures include stripping of the genial tubercle from the lingual cortex of the bone segment, osseous segment necrosis, fracture of the labial cortex, fracture of the mandible, violation of tooth roots, and neurosensory changes. The incidence of these complications appears to be very low.

MMA is an alternative therapeutic option that is highly effective for treating patients with OSA. The combination of a Le Fort I osteotomy with a BSSO creates significant enlargement of the pharyngeal airway space [15]. It seems that in approximately 80–90% of OSA cases treated with MMA that AHI was successfully increased after surgery [16]. The most frequently described complication associated with MMA procedures (not specific for OSA) is the loss of neurosensory function in the IAN, with a reported incidence of 0–85% in non OSA patients [17]. Retrospective analysis revealed an increased age was an important factor in manifestations of complications [18].

Tongue base reduction is aiming the reduction of posterior tongue volume and to widen the space of the upper airway. The da Vinci robot has been validated and is now approved by Food and Drug Administration as an adjunct to transoral surgery. The robot has proved useful in transoral resection of oropharyngeal surgery and has also been used in parapharyngeal space surgery [11].

DO was first reported in 1905 by Codivilla [19] and popularized in the 1950s by Ilizarov, a Russian orthopedic surgeon [20]. The first report of mandibular DO for human patients was in 1992 by McCarthy and colleagues [21]. Mandibular lengthening by DO is now a frequently used technique to correct congenital and acquired craniofacial deformities requiring skeletal expansion. DO is a minimally invasive alternative to standard osteotomies and acute bone lengthening. The operation is of lesser magnitude and shorter duration than traditional techniques. Skeletal and soft tissue expansion of great magnitude can be achieved without the use of bone grafts and soft tissue flaps. DO requires precise preoperative planning to ensure that the correct vector of distraction is executed. Patients undergoing this operation must be carefully selected to ensure that they, or their families, are able to adequately activate and care for the appliances [11].

A relatively recent introduced procedure for OSA is hypoglossal nerve stimulation (HGNS). This technical issues have been addressed in a new-generation implantable HGN stimulation (HGNS) therapy system that has recently been developed to explore further this OSA treatment modality. Early clinical trials in Australia and the USA have demonstrated improvements in airway patency and airflow without causing arousals from sleep [22]. The HGNS system consisted of an implantable neurostimulator connected to a unilateral (generally right-sided) stimulation lead and two respiration sensing leads. The respiration sensing leads were tunnelled and placed subcutaneously to monitor respiration from changes in thoracic bioimpedance. A software algorithm controlled the delivery of HGN electrical stimulation so that stimulation began just prior to and continued throughout inspiration.

References

1. Pirklbauer, K., Russmueller, G., Stiebellehner, L., Nell, C., Sinko, K., Millesi, G., & Klug, C. (2011). Maxillomandibular advancement for treatment of obstructive sleep apnea syndrome: a systematic review. *Journal of Oral and Maxillofacial Surgery*, 69(6), e165-e176.
2. Ryan, C. M., & Bradley, T. D. (2005). Pathogenesis of obstructive sleep apnea. *Journal of applied physiology*, 99(6), 2440-2450.
3. Force, A. O. S. A. T., & American Academy of Sleep Medicine. (2009). Clinical guideline for the evaluation, management and long-term care of obstructive sleep apnea in adults. *Journal of clinical sleep medicine: JCSM: official publication of the American Academy of Sleep Medicine*, 5(3), 263.
4. Gottsauner-Wolf, S., Laimer, J., & Bruckmoser, E. (2017). Posterior airway changes following orthognathic surgery in obstructive sleep apnea. *Journal of Oral and Maxillofacial Surgery*.
5. Fairbanks, D. N. (1990). Uvulopalatopharyngoplasty complications and avoidance strategies. *Otolaryngology—Head and Neck Surgery*, 102(3), 239-245.
6. Riley, R. W., Powell, N. B., & Guilleminault, C. (1993). Obstructive sleep apnea syndrome: a review of 306 consecutively treated surgical patients. *Otolaryngology—Head and Neck Surgery*, 108(2), 117-125.
7. Rojas, R., Chateau, R., Gaete, C., & Muñoz, C. (2018). Genioglossus muscle advancement and simultaneous sliding genioplasty in the management of sleep apnoea. *International journal of oral and maxillofacial surgery*, 47(5), 638-641.
8. Hochban, W., Conradt, R., Brandenburg, U., Heitmann, J., & Peter, J. H. (1997). Surgical maxillofacial treatment of obstructive sleep apnea. *Plastic and reconstructive surgery*, 99(3), 619-26.
9. Robinson, S., Krishnan, S., Hodge, J. C., & Foreman, A. (2012). Conventional tongue base volumetric reduction for obstructive sleep apnea. *Operative Techniques in Otolaryngology-Head and Neck Surgery*, 23(1), 36-44.

10. Steinbacher, D. M., Kaban, L. B., & Troulis, M. J. (2005). Mandibular advancement by distraction osteogenesis for tracheostomy-dependent children with severe micrognathia. *Journal of oral and maxillofacial surgery*, 63(8), 1072-1079.
11. Bouchard, C., Troulis, M. J., & Kaban, L. B. (2009). Management of obstructive sleep apnea: role of distraction osteogenesis. *Oral and Maxillofacial Surgery Clinics*, 21(4), 459-475.
12. Aurora, R. N., Casey, K. R., Kristo, D., Auerbach, S., Bista, S. R., Chowdhuri, S., ... & Morgenthaler, T. I. (2010). Practice parameters for the surgical modifications of the upper airway for obstructive sleep apnea in adults. *Sleep*, 33(10), 1408-1413.
13. Brookes, C. C. D., & Boyd, S. B. (2017). Controversies in Obstructive Sleep Apnea Surgery. *Oral and Maxillofacial Surgery Clinics*, 29(4), 503-513.
14. Vega, J. R. G., de la Plata, M. M., Galindo, N., Navarro, M., Díez, D., & Lánçara, F. (2014). Genioglossus muscle advancement: a modification of the conventional technique. *Journal of Cranio-Maxillo-Facial Surgery*, 42(3), 239-244.
15. Butterfield, K. J., Marks, P. L., McLean, L., & Newton, J. (2015). Linear and volumetric airway changes after maxillomandibular advancement for obstructive sleep apnea. *Journal of Oral and Maxillofacial Surgery*, 73(6), 1133-1142.
16. Zaghi, S., Holty, J. E. C., Certal, V., Abdullatif, J., Guillemineault, C., Powell, N. B., ... & Camacho, M. (2016). Maxillomandibular advancement for treatment of obstructive sleep apnea: a meta-analysis. *JAMA Otolaryngology–Head & Neck Surgery*, 142(1), 58-66.
17. Agbaje, J. O., Salem, A. S., Lambrichts, I., Jacobs, R., & Politis, C. (2015). Systematic review of the incidence of inferior alveolar nerve injury in bilateral sagittal split osteotomy and the assessment of neurosensory disturbances. *International journal of oral and maxillofacial surgery*, 44(4), 447-451.
18. de Ruyter, M. H. T., Apperloo, R. C., Milstein, D. M. J., & de Lange, J. (2017). Assessment of obstructive sleep apnoea treatment success or failure after maxillomandibular advancement. *International journal of oral and maxillofacial surgery*, 46(11), 1357-1362.
19. Codivilla, A. (1905). On the means of lengthening, in the lower limbs, the muscles and tissues which are shortened through deformity. *JBJS*, 2(4), 353-369.
20. Ilizarov, G. A. (1988). The principles of the Ilizarov method. *Bulletin of the Hospital for Joint Diseases Orthopaedic Institute*, 48(1), 1-11.
21. McCarthy, J. G., Schreiber, J., Karp, N., Thorne, C. H., & Grayson, B. H. (1992). Lengthening the human mandible by gradual distraction.
22. Kezirian, E. J., Goding, G. S., Malhotra, A., O'donoghue, F. J., Zammit, G., Wheatley, J. R., ... & Maddison, K. J. (2014). Hypoglossal nerve stimulation improves obstructive sleep apnea: 12-month outcomes. *Journal of sleep research*, 23(1), 77-83.

